



Treatment of Cutaneous Pseudolymphoma: A Systematic Review

Diana MIGUEL, Melanie PECKRUHN and Peter ELSNER
 Department of Dermatology, University Hospital, Jena, Germany

Cutaneous pseudolymphoma (CPL) is a reactive polyclonal T- or B-cell lymphoproliferative process. CPL may appear as localized or disseminated skin lesions. While most cases of CPL are idiopathic, they may also occur as a response to, for example, contact dermatitis, arthropod reactions, and bacterial infections. CPL can be classified based on its clinical features, but all variants have similar histopathological patterns of either predominantly B-cell infiltrates, T-cell infiltrates, or mixed T/B-cell infiltrates. The prognosis of CPL is good, but the underlying disease process should be taken into account. If an antigenic stimulus is identified, it should be removed. In patients with idiopathic CPL, a close follow-up control strategy should be adopted. The aim of this systematic review is to summarize all reported treatments for CPL. The review was based on articles from the PubMed database, using the query "skin pseudolymphoma treatment", English and German, about "human" subjects, and published between 1990 and 2015 documenting adequate treatment and/or aetiology. Mainly individual case reports and small case series were found. Treatment options include topical and intralesional agents, systemic agents, and physical modalities. The final part of the review proposes a treatment algorithm for CPL according to each aetiology, based on the literature of the last 25 years. Future research should focus on randomized controlled trials and studies on long-term outcomes, which were not identified in the current review.

Key words: cutaneous pseudolymphoma; cutaneous lymphoid hyperplasia; treatment; lymphadenosis benigna cutis; lymphocytoma cutis.

Accepted Nov 13, 2017; Epub ahead of print Nov 14, 2017

Acta Derm Venereol 2018; 98: 310–317.

Corr: Diana Miguel, Department of Dermatology, University Hospital, Erfurter Str. 35, DE-07740 Jena, Germany. E-mail: Diana.Miguel@med.uni-jena.de

Cutaneous pseudolymphoma (CPL) is a reactive polyclonal T- or B-cell lymphoproliferative process that develops in reaction to diverse known and unknown stimuli, which can be localized or disseminated in the skin. Pseudolymphomas are also denominated cutaneous lymphoid hyperplasia (CLH), which better describes their benign clinical course. Sarcomatosis cutis, lymphocytoma cutis, lymphadenosis benigna cutis, pseudolymphoma of Spiegler and Fendt, and actinic reticuloid are other accepted terminologies to describe CPL (1, 2). Most cases of CPL are idiopathic. Reactive

responses that can result in CPL include responses to contact dermatitis, lichenoid pigmented purpuric dermatosis, lichen sclerosus et atrophicus, the inflammatory stage of morphea, secondary syphilis, lupus panniculitis, arthropod reactions, nodular scabies, viral infections (orf, milker's nodule, herpes simplex/zoster, and molluscum contagiosum), tattoo dye, vaccinations, trauma, jewellery for pierced ears, such as gold, acupuncture, infections with *Borrelia burgdorferi* or leishmaniasis, and drug reactions (3). Drugs associated with the development of CPL include anticonvulsants, antipsychotics, anti-hypertensives, cytotoxics, antirheumatics, antibiotics, anxiolytics, antihistamines, antiarrhythmics, sex steroids, lipid-lowering agents, and more recently, anti-tumour necrosis factor (TNF)- α agents, tocilizumab, and cyclosporine (1, 4–6). Although they appear more often in the skin, pseudolymphomas have also been described in other organs, such as the eye, tongue, parotid gland, larynx, gastrointestinal tract, lung, kidney, and breast (4).

DIAGNOSTIC FEATURES

In order to diagnose CPL it is important to understand that neither clinical nor histological features alone allow correct classification as lymphoma or pseudolymphoma. Only a combination of clinical signs, histological features and the course of the disease can result in the correct diagnosis. Sometimes a careful drug history, serological tests and patch tests may help to distinguish CPL from lymphoma.

Nevertheless, and because progression of CPL to malignant lymphoma can occur, perhaps induced by persistent antigenic stimulation, regular follow-up of the patient is mandatory (7). However, progression to cutaneous lymphoma has been observed in only a minority of cases.

Clinical signs and course

Clinically, CPL may present as papules, infiltrated plaques and nodules (see examples in **Figs 1** and **2**), less frequently as persistent erythema or exfoliative erythroderma. Even though there is no single clinical feature that proves a malignant or benign lesion, multiple nodules or plaques substantiate the suspicion of a malignant lymphoma. Lymphadenopathy is also more suggestive for lymphoma (8). Nonetheless, the mixed type of B- and T-cell CPL may also show lymphadenopathy.

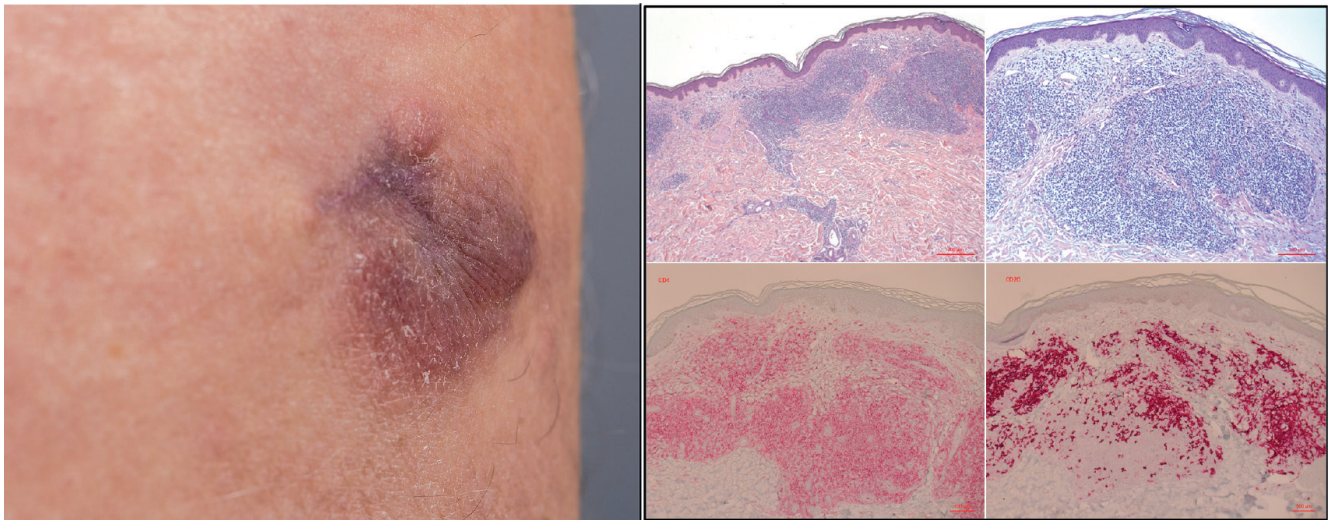


Fig. 1. Pseudolymphoma (a) Clinical picture of the skin. A 2 cm blue-reddish nodule on the right limb. (b) Histopathology. Dense infiltrate of lymphocytes in the upper dermis that are positive for T-(CD4) and B-(CD20) cell-markers (H&E $\times 50$, $\times 100$, CD4, CD20).

Histopathology

Histopathology is an important tool in the diagnosis of CPL, and is necessary to distinguish CPL from reactive cutaneous inflammatory cell infiltrates, and lymphoma. No single histological feature alone can confirm the diagnosis of lymphoma or pseudolymphoma. Each sign is only more suggestive of a malign or benign behaviour of a neoplasm. Even the combination of histological features cannot confirm a CPL. Histopathologically CPL can be differentiated by the predominant cells in the infiltrate (**Table I**) (9, 10). In contrast to the WHO/European Organization for Research and Treatment of Cancer (WHO-EORTC) classification of cutaneous lymphoma, there is currently no established classification of pseudolymphomas.

Important histological characteristics of CPL that help to distinguish it from other benign cutaneous inflammatory cell infiltrates are the presence of variable numbers of medium- to large-sized lymphocytes, which may appear atypical, alongside many ordinary small lympho-

cytes and other inflammatory cells. Most CPLs consist of mixtures of B and T cells along with macrophages and dendritic cells (3).

Various histopathological features favour a lymphoma over a CPL:

- bottom-heavy infiltrate (deep infiltrate down to the subcutaneous fat);
- monomorphic infiltrate;
- high-grade atypical lymphocytes (changes in nuclear morphology, changes in nuclear density, changes in nucleus/cytoplasm ratio).

However, CPL may be histopathologically indistinguishable from cutaneous lymphoma. This important differentiation may require additional tests, such as immunohistochemistry or gene rearrangement (3).

Immunohistochemistry differentiates lymphocytes by their immune-phenotype (surface markers), e.g. assignment to B or T cells. A mixed B- and T-cell infiltrate is more suggestive for CPL. A loss of typical T-cell-surface-markers (e.g. CD2, CD3, CD5), may be seen in progressed T-cell-lymphoma.

The diagnosis of CPL is backed by negative T-cell receptor rearrangement (monoclonality), missing plasma cell (mono-)clonality, negative immunoglobulin heavy chain gene rearrangements and polyclonal kappa and lambda light chains (3, 11–13).

Management of CPL may be difficult, with several treatment regimens, including topical and intralesional agents, systemic agents and physical modalities, showing variable dermatological responses.

We review here the treatment of pseudolymphoma of the skin according to its aetiology. We also suggest a treatment algorithm that may help physicians in choosing treatment. There is no previous systematic review of the treatment of CPL.

Table I. Cutaneous pseudolymphoma can be differentiated according to the predominant cells in the infiltrate

Predominant lymphocyte subtype	Disease entity
T-cell pseudolymphoma	Lymphocytic infiltration Jessner-Kanof Actinic reticuloid Lymphomatoid contact dermatitis
B-cell pseudolymphoma	Lymphadenosis cutis benigna Arthropod-bite reaction Vaccination Tattoo ink-related Cutaneous inflammatory pseudotumour
Mixed (B and T)-cell pseudolymphoma	Lymphomatoid drug reaction
CD-30-positive pseudolymphoma	Scabies Herpes Milker's nodule
Non-classifiable pseudolymphoma	Descriptive diagnosis for other atypical lymphocytic infiltrations

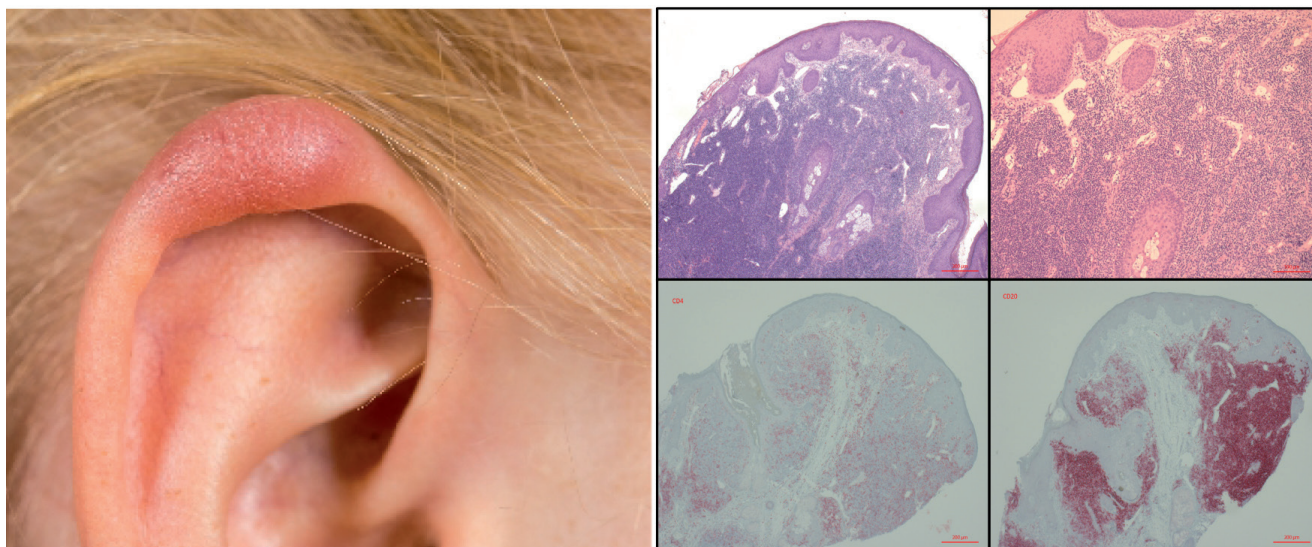


Fig. 2. Lymphadenosis cutis benigna. (a) Clinical features – 10×8 mm soft nodule at the helix of the right ear. (b) Histopathology: dense deep lymphocytic infiltrates affecting the deep dermis with CD4-positive Lymphocytes and CD20 positive B-Cells (H&E ×50, ×100, CD4, CD20).

METHODS

A systematic review was performed following the Preferred Reporting Items for Systematic Reviews and Meta-Analysis (PRISMA) based on PubMed, Medline and Web of Science databases using the query “skin pseudolymphoma treatment”. Our search was limited to “English” and “German” language, “human” subjects and publications from 1 January 1990 to 31 December 2015 documenting aetiology and/or adequate treatment for CPL. Furthermore, the references of the retrieved articles were searched manually for additional studies. The reference lists of the full-length articles were reviewed to identify additional articles meeting the pre-defined inclusion criteria. Articles in which pseudolymphoma was labelled as lymphocytoma cutis, lymphocytoma cutis benigna or lymphoid hyperplasia were included. Reviews and articles from the same department, in which some patients could have been described twice, were excluded. Table S1¹ presents a summary of the characteristics of the included studies (author/study year, country, study design and number of patients). Data on sex/age, aetiology, time of onset, histological features, treatment and outcome were also collected. Descriptive statistics were used for the evaluation of sex/age and aetiology.

RESULTS

A total of 192 articles was identified from the initial search, of which 80 met the inclusion criteria. Three additional articles were found through the manual review. After searching in Medline and Web of Science databases, no further articles were added to the initial search. After reviewing all full-text articles and excluding reviews or papers about other diseases, a total of 83 studies; 80 from the initial search and 3 from additional papers, were analysed.

The results are based mostly on individual case reports and small case series. Treatment options should

be decided first, according to CPL aetiology (**Fig. 3**). Treatment can be divided into topical and intralesional agents, systemic agents and physical modalities. Patient outcomes may vary, with the aetiology of the lesion playing an important role. Reported treatment regimens were often unsuccessful.

Patient characteristics, aetiology and time of onset

A total of 122 patients with pseudolymphoma of the skin were identified. The mean age of diagnosis was 42 years ($n=106$), and the female:male ratio was 1:1 ($n=107$). Data about the aetiology of the CPL were available for 106 patients (**Fig. 4**). The most frequently reported aetiology was CPL induced by drugs ($n=31$), followed by tattoo reactions ($n=28$).

Treatment according to cutaneous pseudolymphoma aetiology

Tattoo ink-related CPL. The literature review revealed 26 patients with CPL after tattooing. The pathogenesis remains obscure, but it is suggested that some metal components (cinnabar (red), cobalt salts (blue) and chromium salts (green)) are responsible for a delayed hypersensitivity reaction (8).

Surgery should be performed for tattoo ink-related CPL whenever possible. All the patients in our review who underwent a surgical procedure ($n=6$) had complete healing, with no skin relapse or recurrence reported.

A total of 8 patients with CPL due to ink-tattoo reaction were treated with topical or intralesional corticosteroids. Six patients had a poor response after therapy, with one patient showing progression to frank lymphoma after 7 years (14–18). Only 2 patients experienced an improvement in the skin lesions (19, 20). One patient

¹<https://www.medicaljournals.se/acta/content/abstract/10.2340/00015555-2841>

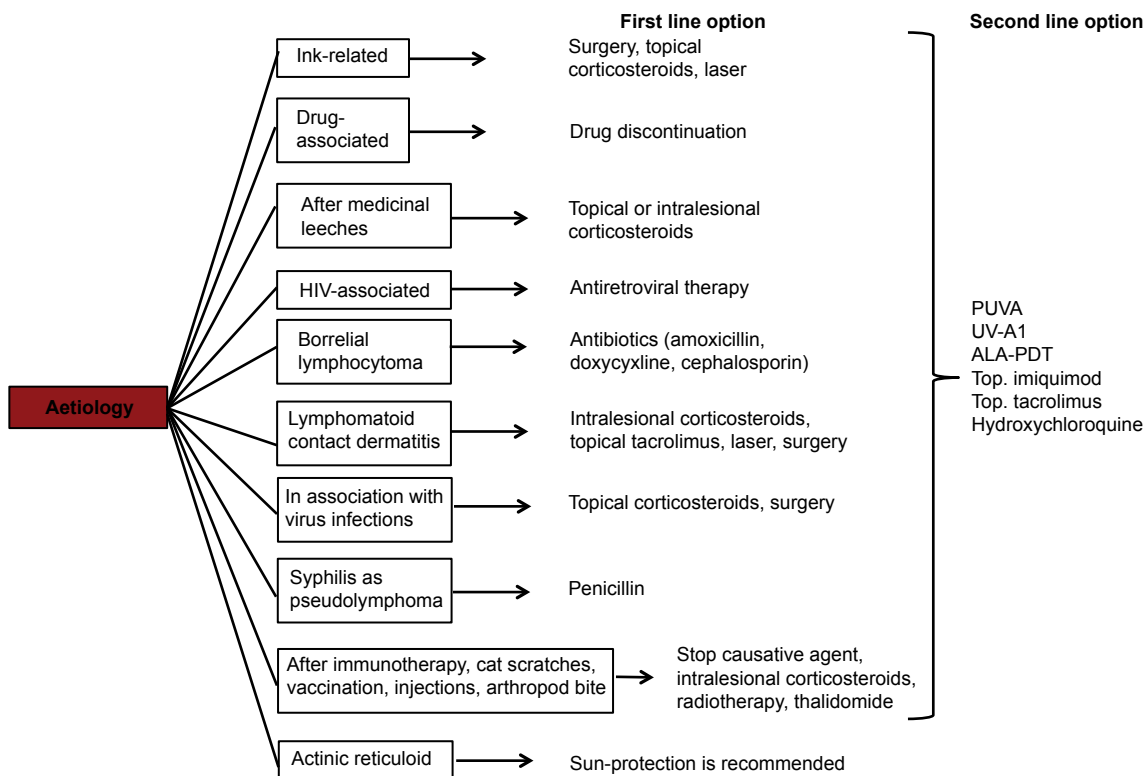


Fig. 3. Suggested classification and first- and second-line treatment for CPL. PUVA: psoralen and ultraviolet A therapy, UVA1: ultraviolet A1 therapy, ALA-PDT: photodynamic therapy with aminolevulinic acid, Top: topical treatment.

was successfully treated with topical corticosteroids in combination with oral hydroxychloroquine (21). Regular follow-up is recommended due to possible progression to malignancy.

Four patients with tattoo ink-related CPL were treated with laser. Q-switched neodymium:yttrium-aluminium-garnet laser or CO₂ laser usually resulted in marked improvement in the skin lesions and in 2 of these 4 patients, intralesional corticosteroid adjuvant therapy was performed (17, 20, 22, 23).

Drug-associated CPL. Reports on 31 patients who developed drug-induced CPL were found. Medicaments responsible for causing CPL found in the review include: phenytoin, vancomycin, rifampicin, amlodipine, cefepime, sertraline, gabapentin, valsartan, etanercept, methylphenidate hydrochloride, lornoxicam, gemcitabine, carbamazepine, tricyclic antidepressant, fluoxetine, H1 antagonist, H2 antagonist, phenothiazine and thioridazine. Magro et al. suggested that antihistamines may be associated with atypical lymphoid hyperplasia in some patients (24, 25). Other drugs that can be involved in cutaneous pseudolymphomatous reactions are angiotensin-converting enzyme (ACE) inhibitors, beta-blockers, calcium channel blockers, diuretics, cytotoxic agents (cyclosporin, methotrexate), rheumatology drugs (gold, salicylates, phenacetin, D-penicillamine, allopurinol, non-steroidal anti-inflammatory drugs (NSAIDs)), antibiotics, benzodiazepines, procainamide, oestrogens, progesterone and lovastatin (26). In a recent paper by Safa et al. (27), a female patient developed erythrodermic CD8⁺ pseudolymphoma during infliximab treatment and was treated successfully with cyclosporin after cessation of infliximab therapy. CPL may also appear in association with etanercept therapy (28).

In all patients with drug-associated CPL described here, the time of onset varied between 1 day and 15 years. The skin lesions resolved completely after drug discontinuation and the time period of regression ranged from a few weeks to few months.

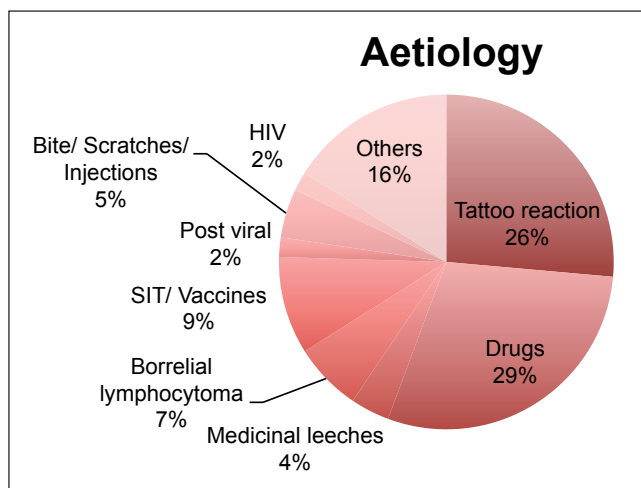


Fig. 4. Aetiology of cutaneous pseudolymphoma (n = 106). SIT: specific immunotherapy.

Following therapy with medicinal leeches. Four patients developed CPL after therapy with medicinal leeches (*Hirudo medicinalis*). Medicinal leeches are used to treat chronic venous insufficiency, osteoarthritis and myalgia. Treatment with topical and/or intralesional corticosteroids resulted in improvement in the skin disease (29–32).

HIV-associated CPL. Two patients presented with a HIV-associated atypical cutaneous CD8⁺ T-cell infiltrate, which is usually associated with severe CD4 lymphopenia (33). Its pathogenesis is unknown. One patient showed a decrease in the number of lesions after receiving systemic antiretroviral therapy with ritonavir, atazanavir, emtricitabine, tenofovir and oral prednisolone, and the other patient responded with a dramatic improvement in skin lesions after therapy with lamivudine, stavudine and indinavir (34, 35).

Borrelial lymphocytoma – lymphadenosis benigna cutis. This rare cutaneous manifestation of Lyme borreliosis appears in the early phase of infection, between 2 days and 6 months after a tick bite. Borrelial lymphocytomas are more common in children, and they are found mostly in the ear lobe, scrotum, and nipples (36). The gold standard treatment of borrelial lymphocytoma is treatment of the underlying infection with antibiotics, such as penicillin, doxycycline or cephalosporin. Only in rare cases, might other options apply: Aydogan et al. reported a male patient with borrelial lymphocytoma cutis resistant to penicillin and doxycycline treatment, who later responded to intralesional therapy with low-dose interferon-alpha-2a (37).

After immunotherapy, cat scratches, vaccination, injections, and arthropod bites. Yalcin et al. reported a case of Jessner's lymphocytic infiltrate 3 weeks after initiation of bee venom immunotherapy, and 2 female patients developed B-cell pseudolymphoma shortly after initiation of a specific immune therapy (38, 39). In these cases, pseudolymphoma may resolve after immunotherapy is stopped.

Another case in a child suggested cutaneous lymphoid hyperplasia secondary to recurrent inoculation of *Bartonella henselae* due to feline scratches. The lesions responded to azithromycin and disappeared completely after the cat died (40).

Vaccine-induced CPL is rare, and its pathogenesis remains unknown, but some authors suggest that CPL may result from a delayed hypersensitivity reaction to vaccine components. This may be seen in vaccines containing aluminium, due to its contribution to a delayed absorption of other components, thereby promoting an antigen stimulus (41). In one patient, skin lesions disappeared after treatment with thalidomide 12 years after the onset of the disease in a patient with B-cell CPL after hepatitis B vaccination (42). In a case series of Cerroni et al., 4 female patients developed B-cell CPL after vaccination against early summer meningoencephalitis, tetanus and

hepatitis B. Two patients were treated successfully with radiotherapy (43).

One patient with CPL associated with silicone injection and one with CPL at the site of a clonidine patch showed improvement of the lesions after treatment with triamcinolone acetonide injection.

Scabies mites may cause nodular scabies, histologically simulating mycosis fungoides or even cutaneous B-cell lymphoma. It has been postulated that this disease course occurs due to a delayed hypersensitivity reaction. Other arthropods may also cause this type of persistent reactions. Cases of skin pseudolymphoma caused by cutaneous leishmaniasis have also been reported (44, 45).

Lymphomatoid contact dermatitis. Having similar features with mycosis fungoides, but without Pautrier's microabscesses, there are several allergens that may be implicated in lymphomatoid contact dermatitis. Treatment consists mainly in the avoidance of the causative allergens. Allergens implicated include phosphorus, N-Isopropyl-N-phenyl-4-phenylenediamine, ethylenediamine, dihydrochloride, cobalt naphthenate, nickel sulphate, paraphenylenediamine, gold sodium thiosulfate, zinc, squaric acid dibutylester, methylchloroisothiazolinone (26). Millican et al. reported a first case of CLH after sensitization with squaric acid dibutylester (46–48). Treatments include local and intralesional corticosteroids and tacrolimus ointments. Laser treatments or surgical excision may also be discussed with the patient. Successful surgical excision was performed in a case of CPL after intradermal testing with gold sodium thiomalate.

CPL in association with virus infections: herpes zoster, and molluscum contagiosum. Moreira et al. reported a patient with B-cell chronic lymphocytic leukaemia developing post-zoster CPL, which was treated with topical corticosteroids leaving a macular hyperpigmentation (49). Another case of CPL with this aetiology was published in 1987 (50). Surgical excision was performed in a female patient with CPL in association with molluscum contagiosum and the lesion did not recur (51).

Syphilis presenting as pseudolymphoma. With syphilis being the great imitator, clinicians should be aware of its many different clinical presentations and, especially, of a nodular form. A patient with nodular plaques with histological findings of a pseudolymphoma was treated with benzathine penicillin and all skin lesions cleared (52). Some cases of syphilis are clinically indistinguishable from lymphomatoid papulosis. Abundant plasma cells and spirochetes in the histology may help to differentiate them. Rash lesions resolve after treatment with antibiotics. Eleven other cases of syphilis have been reported to histologically mimic a malignant lymphoid neoplasm (52, 53).

Actinic reticuloid. This chronic photodermatitis, usually affecting male older patients, is characterized by extreme

photosensitivity. It is suggested that, due to alterations induced by a photoallergic reaction, normal components of the skin change into “antigens”. There is no cure, and sun-protection is recommended (54, 55).

Other treatments

Psoralen plus ultraviolet A and long-wave ultraviolet A therapy. A recent report showed good results in a patient with lymphocytoma cutis (Spiegler-Fendt sarcoid) after therapy with 13 sessions of psoralen plus ultraviolet A (PUVA) and 5 sessions of intralesional triamcinolone (56). In another case, PUVA was the therapy of choice of a solitary T-cell pseudolymphoma of the breast (57). Long-wave ultraviolet A (UVA1) in a young man having palpable migratory arciform erythema led to complete regression of the skin lesions (58).

5-aminolevulinic acid photodynamic therapy. Treatment with ALA-PDT was reported in 4 patients with CPL of the face, leading to marked improvement in the skin lesions. In 1 patient there was no recurrence (59–61).

Topical tacrolimus. Two patients with lymphocytoma cutis of the head and neck with idiopathic aetiology showed slow clinical improvement (>4 months) of the affected skin while using topical tacrolimus 0.1% (62). Nevertheless, spontaneous regression of CPL was reported (63).

Topical imiquimod. This immunomodulator (Toll-like receptor 7 inhibitor) may be an efficient treatment alternative for CPL. Topical treatment with imiquimod 5% resulted in total clearance of the affected skin after treatment failure with topical steroids, antimalarials combined with tacrolimus 0.1%, photodynamic therapy, ultraviolet B (UVB) and oral penicillin (64).

Hydroxychloroquine sulphate. Treatment with hydroxychloroquine sulphate (400 mg/day) for 3 months was successful in an individual with pseudolymphoma cutis without any causal factor, and this patient remained disease-free at one year of follow-up (65). One woman, having miliarial-type perifollicular B-cell pseudolymphoma, had an improvement of the skin lesions after treatment with hydroxychloroquine (66). A hypothesis providing a rationale for treatment with hydroxychloroquine is the presence of plasmacytoid dendritic cells in CPL, as these cells respond to hydroxychloroquine (67). We suggest the use of hydroxychloroquine in patients with CPL with unknown aetiology in whom excision cannot be performed. However, dermatologists should be aware that this recommendation is based on only a few case reports.

CONCLUSION

CPLs are a group of diseases that exhibit a lymphocyte-rich infiltrate, which either clinically and/or histologically simulate cutaneous lymphomas (68).

A wide range of causative agents has been described, and treatment may thus be difficult. Many different modalities have been reported. Following a systematic review of the literature of the last 25 years we suggest that treatment options should be chosen based on the specific aetiology (Fig. 4). While there are a considerable number of publications on the histopathology and classification of CPL, reports on treatment options are lacking, with much of the published work not disclosing any information about successful treatments and (long-term) outcomes. More reports of cases of CPL are needed, whether successfully treated or not, in order to avoid publication bias under-reporting poor outcomes or overestimating the response rates. Randomized controlled trials are difficult due to the rarity of CPL, and a gold standard therapy cannot be suggested. Treatment choice should be made individually for each patient according to aetiology and localization. A large proportion of cases of CPL are idiopathic and, if no surgical excision is performed, watchful follow-up is highly recommended due to the possible progress of CPL to malignant lymphoma.

The authors have no conflict of interest to declare.

REFERENCES

1. Ploysangam T, Breneman DL, Mutasim DF. Cutaneous pseudolymphomas. *J Am Acad Dermatol* 1998; 38: 877–895; quiz 896–877.
2. Nihal M, Mikkola D, Horvath N, Gilliam AC, Stevens SR, Spiro TP, et al. Cutaneous lymphoid hyperplasia: a lymphoproliferative continuum with lymphomatous potential. *Human Pathol* 2003; 34: 617–622.
3. Bergman R. Pseudolymphoma and cutaneous lymphoma: facts and controversies. *Clin Dermatol* 2010; 28: 568–574.
4. Joseph D, Irukulla MM, Ahmed SF, Valiyaveetil D, Akram S. Radiotherapy in aggressive cutaneous pseudolymphoma: a case report and review of literature. *Rad Oncol J* 2016; 34: 76–80.
5. Inoue A, Sawada Y, Ohmori S, Omoto D, Haruyama S, Yoshioka M, et al. CD30-positive cutaneous pseudolymphoma caused by tocilizumab in a patient with rheumatoid arthritis: case report and literature review. *Acta Derm Venereol* 2016; 96: 570–571.
6. Foley C, Leonard N, Wynne B. Cutaneous pseudolymphoma: a rare side effect of cyclosporine. *J Am Acad Dermatol* 2015; 72: e85–86.
7. Sanguenza OP, Yadav S, White CR, Jr, Braziel RM. Evolution of B-cell lymphoma from pseudolymphoma. A multidisciplinary approach using histology, immunohistochemistry, and Southern blot analysis. *Am J Dermatopathol* 1992; 14: 408–413.
8. Marchesi A, Parodi PC, Brioschi M, Marchesi M, Bruni B, Cangi MG, et al. Tattoo ink-related cutaneous pseudolymphoma: a rare but significant complication. Case report and review of the literature. *Aesthetic Plast Surg* 2014; 38: 471–478.
9. Wolf IH, Cerroni L, Fink-Puches R, Kerl H. Das morphologische Spektrum der kutanen Pseudolymphome. *J Dtsch Dermatol Ges* 2005; 3: 710–720; quiz 721.
10. Kerl H, Fink-Puches R, Cerroni L. Diagnostic criteria of primary cutaneous B-cell lymphomas and pseudolymphomas. *Keio J Med* 2001; 50: 269–273.
11. Leinweber B, Colli C, Chott A, Kerl H, Cerroni L. Differential diagnosis of cutaneous infiltrates of B lymphocytes with follicular growth pattern. *Am J Dermatopathol* 2004; 26: 4–13.
12. Hammer E, Sanguenza O, Suwanjindar P, White CR, Jr, Braziel RM. Immunophenotypic and genotypic analysis in cutaneous lymphoid hyperplasias. *J Am Acad Dermatol* 1993; 28: 426–433.

13. Bouloc A, Delfau-Larue MH, Lenormand B, Meunier F, Wechsler J, Thomine E, et al. Polymerase chain reaction analysis of immunoglobulin gene rearrangement in cutaneous lymphoid hyperplasias. French Study Group for Cutaneous Lymphomas. Arch Dermatol 1999; 135: 168–172.
14. Cristaudo A, Forte G, Bocca B, Petrucci F, Muscardin L, Trento E, et al. Permanent tattoos: evidence of pseudolymphoma in three patients and metal composition of the dyes. Eur J Dermatol 2012; 22: 776–780.
15. Souza ES, Rocha Bde O, Batista Eda S, Oliveira RF, Farre L, Bittencourt AL. T-cell-predominant lymphoid hyperplasia in a tattoo. An Bras Dermatol 2014; 89: 1019–1021.
16. Cruz FA, Lage D, Frigerio RM, Zaniboni MC, Arruda LH. Reactions to the different pigments in tattoos: a report of two cases. An Bras Dermatol 2010; 85: 708–711.
17. Kluger N, Vermeulen C, Moguelet P, Cotten H, Koeb MH, Balme B, et al. Cutaneous lymphoid hyperplasia (pseudolymphoma) in tattoos: a case series of seven patients. J Eur Acad Dermatol Venereol 2010; 24: 208–213.
18. Munoz C, Guilabert A, Mascaro JM, Jr., Lopez-Lerma I, Vilaplana J. An embossed tattoo. Clin Exp Dermatol 2006; 31: 309–310.
19. Chave TA, Mortimer NJ, Johnston GA. Simultaneous pseudolymphomatous and lichenoid tattoo reactions triggered by re-tattooing. Clin Exp Dermatol 2004; 29: 197–199.
20. Shin JB, Seo SH, Kim BK, Kim IH, Son SW. Cutaneous T cell pseudolymphoma at the site of a semipermanent lip-liner tattoo. Dermatology 2009; 218: 75–78.
21. Patrizi A, Raone B, Savoia F, Bacchi F, Pileri A, Gurioli C, et al. Tattoo-associated pseudolymphomatous reaction and its successful treatment with hydroxychloroquine. Acta Derm Venereol 2009; 89: 327–328.
22. Campolmi P, Bassi A, Bonan P, Cannarozzo G, Gola M, Rossi Degl'Innocenti D, et al. Cutaneous pseudolymphoma localized to black tattoo. J Am Acad Dermatol 2011; 65: e155–157.
23. Chiang C, Romero L. Cutaneous lymphoid hyperplasia (pseudolymphoma) in a tattoo after far infrared light. Dermatol Surg 2009; 35: 1434–1438.
24. Pulitzer MP, Nolan KA, Oshman RG, Phelps RG. CD30+ lymphomatoid drug reactions. Am J Dermatopathol 2013; 35: 343–350.
25. Magro CM, Crowson AN. Drugs with antihistaminic properties as a cause of atypical cutaneous lymphoid hyperplasia. J Am Acad Dermatol 1995; 32: 419–428.
26. Romero-Perez D, Blanes Martinez M, Encabo-Duran B. Cutaneous pseudolymphomas. Actas Dermosifiliograf 2016; 107: 640–651.
27. Safa G, Luce K, Darrieux L, Tisseau L, Ortonne N. Erythrodermic CD8+ pseudolymphoma during infliximab treatment in a patient with psoriasis: use of cyclosporine as a rescue therapy. J Am Acad Dermatol 2014; 71: e149–150.
28. Guis S, Schiano de Colella JM, Bonnet N, Andrac-Meyer L, Balandraud N, Mattei JP, et al. Cutaneous pseudolymphoma associated with a TNF-alpha inhibitor treatment: etanercept. Eur J Dermatol 2008; 18: 474–476.
29. Altamura D, Calonje E, Liu J, Rogers M, Verdolini R. Diffuse cutaneous pseudolymphoma due to therapy with medicinal leeches. JAMA Dermatol 2014; 150: 783–784.
30. Khelifa E, Kaya G, Laffitte E. Cutaneous pseudolymphomas after leech therapy. J Dermatol 2013; 40: 674–675.
31. Choi Y, Kim SC. Cutaneous pseudolymphoma induced by Hirudo medicinalis therapy. J Dermatol 2012; 39: 195–197.
32. Smolle J, Cerroni L, Kerl H. Multiple pseudolymphomas caused by Hirudo medicinalis therapy. J Am Acad Dermatol 2000; 43: 867–869.
33. Guitart J, Variakojis D, Kuzel T, Rosen S. Cutaneous CD8 T cell infiltrates in advanced HIV infection. J Am Acad Dermatol 1999; 41: 722–727.
34. Fernandez-Morano T, Aguilar-Bernier M, Del Boz J, Funez-Liebana R. Cutaneous CD8+ T-cell infiltrates associated with human immunodeficiency virus. Actas Dermosifiliograf 2012; 103: 638–640.
35. Schartz NE, De La Blanchardiere A, Alaoui S, Morel P, Sigaux F, Vignon-Pennamen MD, et al. Regression of CD8+ pseudolymphoma after HIV antiviral triple therapy. J Am Acad Dermatol 2003; 49: 139–141.
36. Moniuszko A, Czupryna P, Pancewicz S, Kondrusik M, Penza P, Zajkowska J. Borrelial lymphocytoma – a case report of a pregnant woman. Ticks Tick Borne Dis 2012; 3: 257–258.
37. Aydogan K, Karadogan SK, Adim SB, Tunali S. Borrelial lymphocytoma cutis successfully treated with intralesional interferon-alpha-2A. J Eur Acad Dermatol Venereol 2006; 20: 1030–1032.
38. Yalcin AD, Bisgin A, Akman A, Erdogan G, Ciftcioglu MA, Yegin O. Jessner lymphocytic infiltrate as a side effect of bee venom immunotherapy. J Invest Allergol Clin Immunol 2012; 22: 308–309.
39. Gerlini G, Mori M, Massi D, Pimpinelli N. Specific immune therapy-related cutaneous B-cell pseudolymphoma with following dissemination. J Eur Acad Dermatol Venereol 2003; 17: 208–212.
40. Madhogaria S, Carr RA, Gach JE. Childhood cutaneous lymphoid hyperplasia following feline scratches. Pediatr Dermatol 2010; 27: 294–297.
41. Guillard O, Fauconneau B, Pineau A, Marraud A, Bellocq JP, Chenard MP. Aluminium overload after 5 years in skin biopsy following post-vaccination with subcutaneous pseudolymphoma. J Trace Elem Med Biol 2012; 26: 291–293.
42. Pham-Ledard A, Vergier B, Doutre MS, Beylot-Barry M. Disseminated cutaneous lymphoid hyperplasia of 12 years' duration triggered by vaccination. Dermatology 2010; 220: 176–179.
43. Cerroni L, Borroni RG, Massone C, Chott A, Kerl H. Cutaneous B-cell pseudolymphoma at the site of vaccination. Am J Dermatopathol 2007; 29: 538–542.
44. Alhumidi AA. Skin pseudolymphoma caused by cutaneous leishmaniasis. Saudi Med J 2013; 34: 537–538.
45. Recalcati S, Vezzoli P, Girgenti V, Venegoni L, Veraldi S, Berti E. Cutaneous lymphoid hyperplasia associated with Leishmania panamensis infection. Acta Derm Venereol 2010; 90: 418–419.
46. Nishioka K, Ogasawara M, Kurata K, Asagami C. Iatrogenic benign lymphoplasia induced by allergic contact dermatitis from squaric acid dibutylester: immunohistologic study of cellular infiltrates. Contact Dermatitis 1993; 28: 3–5.
47. Yoshida Y, Duan H, Nakayama J, Furue M. Lymphadenosis benigna cutis induced by iatrogenic contact dermatitis from dinitrochlorobenzene. Contact Dermatitis 2003; 49: 165–166.
48. Millican EA, Conley JA, Sheinbein D. Cutaneous lymphoid hyperplasia related to squaric acid dibutyl ester. J Am Acad Dermatol 2011; 65: 230–232.
49. Moreira E, Lisboa C, Azevedo F, Principe F, Lima M. Postzoster cutaneous pseudolymphoma in a patient with B-cell chronic lymphocytic leukaemia. J Eur Acad Dermatol Venereol 2007; 21: 1112–1114.
50. Wolff HH, Wendt V, Winzer M. Cutaneous pseudolymphoma at the site of prior herpes zoster eruption. Arch Dermatol Res 1987; 279 Suppl: S52–54.
51. Moreno-Ramirez D, Garcia-Escudero A, Rios-Martin JJ, Herrera-Saval A, Camacho F. Cutaneous pseudolymphoma in association with molluscum contagiosum in an elderly patient. J Cutan Pathol 2003; 30: 473–475.
52. Moon HS, Park K, Lee JH, Son SJ. A nodular syphilid presenting as a pseudolymphoma: mimicking a cutaneous marginal zone B-cell lymphoma. Am J Dermatopathol 2009; 31: 846–848.
53. Hodak E, David M, Rothen A, Bialowance M, Sandbank M. Nodular secondary syphilis mimicking cutaneous lymphoreticular process. J Am Acad Dermatol 1987; 17: 914–917.
54. Toonstra J, Henquet CJ, van Weelden H, van der Putte SC, van Vloten WA. Actinic reticuloid. A clinical photobiologic, histopathologic, and follow-up study of 16 patients. J Am Acad Dermatol 1989; 21: 205–214.
55. Lugovic-Mihic L, Duvancic T, Situm M, Mihic J, Krolo I. Actinic reticuloid – photosensitivity or pseudolymphoma? – A review. Collegium Antropologicum 2011; 35 Suppl 2: 325–329.
56. Oliveira EV, Badiale GB, Moraes MM. Lymphocytoma cutis – case report. An Bras Dermatol 2013; 88: 128–131.

57. Pacheco D, Travassos AR, de Almeida LS, Silva R, Filipe P. Solitary T-cell pseudolymphoma of the breast, treated by PUVA. *Eur J Dermatol* 2013; 23: 397–398.
58. Wagner G, Bartsch S, Rose C, Sachse MM. Erythema migrans arciforme et palpabile. *Hautarzt* 2012; 63: 965–968.
59. O'Neill J, Fien S, Zeitouni NC. ALA-PDT for the treatment of cutaneous pseudolymphoma: a case report. *J Drugs Dermatol* 2010; 9: 688–689.
60. Mikasa K, Watanabe D, Kondo C, Tamada Y, Matsumoto Y. Topical 5-aminolevulinic acid-based photodynamic therapy for the treatment of a patient with cutaneous pseudolymphoma. *J Am Acad Dermatol* 2005; 53: 911–912.
61. Takeda H, Kaneko T, Harada K, Matsuzaki Y, Nakano H, Hanada K. Successful treatment of lymphadenosis benigna cutis with topical photodynamic therapy with delta-aminolevulinic acid. *Dermatology* 2005; 211: 264–266.
62. El-Dars LD, Statham BN, Blackford S, Williams N. Lymphocytoma cutis treated with topical tacrolimus. *Clin Exp Dermatol* 2005; 30: 305–307.
63. Kakizaki A, Fujimura T, Numata I, Hashimoto A, Aiba S. Pseudolymphomatous folliculitis on the nose. *Case Rep Dermatol* 2012; 4: 27–30.
64. Baumgartner-Nielsen J, Lorentzen H. Imiquimod 5%: a successful treatment for pseudolymphoma. *Acta Derm Venereol* 2014; 94: 469.
65. Dragonetti E, Cianchini G, Mastrangelo L, Mellone P, Baldi A. Cutaneous pseudolymphoma: a case report. *In Vivo* 2004; 18: 549–551.
66. Moulouquet I, Ghnassia M, Molina T, Fraïtag S. Miliarial-type perifollicular B-cell pseudolymphoma (lymphocytoma cutis): a misleading eruption in two women. *J Cutan Pathol* 2012; 39: 1016–1021.
67. Kempf W, Kerl H, Kutzner H. CD123-positive plasmacytoid dendritic cells in primary cutaneous marginal zone B-cell lymphoma: a crucial role and a new lymphoma paradigm. *Am J Dermatopathol* 2010; 32: 194–196.
68. Mitteldorf C, Kempf W. Cutaneous pseudolymphoma. *Surg Pathol Clin* 2017; 10: 455–476.
69. Jaehn T, Kaiser A, Gruneis C, Saalabian AA, Reichert B. Pseudolymphomatöse Fremdkörperreaktion nach Tätowierung. *Handchir Mikrochir Plast Chir* 2014; 46: 379–382.
70. Toberer F, Hartschuh W, Kutzner H, Flux K. Erythematous-to-brownish plaques on the upper back: a quiz. Phenytoin-induced T-cell predominant pseudolymphoma ("pseudomycosis fungoides") with T-cell clonality. *Acta Derm Venereol* 2015; 95: 378–382.
71. Chu MB, Dhandha M, Guo A. Coexistent dermatofibrosarcoma protuberans and anticonvulsant-induced cutaneous lymphoid hyperplasia: diagnostic challenge. *BMJ Case Rep* 2013; 2013.
72. Macisaac JL, Ward CE, Pratt M. Cutaneous T-cell lymphoma-like drug eruption in an HIV-positive patient taking vancomycin and rifampin. *J Cutan Med Surg* 2013; 17: 433–436.
73. Koguchi H, Arita K, Nakazato S, Moriuchi R, Yamane N, Shinkuma S, et al. An erythematous plaque on the breast: a quiz. Solitary T-cell pseudolymphoma, superficial type. *Acta Derm Venereol* 2013; 93: 763, 608.
74. Singletary HL, Selim MA, Olsen E. Subcutaneous interferon alfa for the treatment of cutaneous pseudolymphoma. *Arc Dermatol* 2012; 148: 572–574.
75. Moulouquet I, Gantzer A, Bourdon-Lanoy E, Fraïtag S. A pretibial plaque in a five and a half year-old girl. *Am J Dermatopathol* 2012; 34: 113–116.
76. Martin SJ, Duvic M. Treatment of cutaneous lymphoid hyperplasia with the monoclonal anti-CD20 antibody rituximab. *Clin Lymphoma Myeloma Leuk* 2011; 11: 286–288.
77. Kuo WE, Richwine EE, Sheehan DJ. Pseudolymphomatous and lichenoid reaction to a red tattoo: a case report. *Cutis* 2011; 87: 89–92.
78. Sawada Y, Yoshiki R, Kawakami C, Fukamachi S, Sugita K, Nakamura M, et al. Valsartan-induced drug eruption followed by CD30+ pseudolymphomatous eruption. *Acta Derm Venereol* 2010; 90: 521–522.
79. Tomar S, Stoll HL, Grassi MA, Cheney R. Treatment of cutaneous pseudolymphoma with interferon alfa-2b. *J Am Acad Dermatol* 2009; 60: 172–174.
80. Stavrianeas NG, Katoulis AC, Bozi E, Toubis-Ioannou E, Kanelleas AI, Makris M, et al. Cutaneous pseudolymphoma following administration of lornoxicam. *Acta Derm Venereol* 2007; 87: 453–455.
81. Dionyssopoulos A, Mandekou-Lefaki I, Delli FS, Kourtis D, Nikolis A, Dionyssopoulou E, et al. T- and B-cutaneous pseudolymphomas treated by surgical excision and immediate reconstruction. *Dermatol Surg* 2006; 32: 1526–1529.
82. May SA, Netto G, Domiati-Saad R, Kasper C. Cutaneous lymphoid hyperplasia and marginal zone B-cell lymphoma following vaccination. *J Am Acad Dermatol* 2005; 53: 512–516.
83. Lee MW, Choi JH, Sung KJ, Moon KC, Koh JK. A case of cutaneous pseudolymphoma associated with silicone injection. *Acta Derm Venereol* 2004; 84: 312–313.
84. Grange F, Wechsler J, Guillaume JC, Tortel J, Tortel MC, Audhuy B, et al. *Borrelia burgdorferi*-associated lymphocytoma cutis simulating a primary cutaneous large B-cell lymphoma. *J Am Acad Dermatol* 2002; 47: 530–534.
85. Gissler S, Heininger U. *Borrelia* lymphocytoma ("lymphadenosis benigna cutis"). *Arch Dis Childhood* 2002; 87: 12.
86. Marucci G, Sgarbanti E, Maestri A, Calandri C, Collina G. Gemcitabine-associated CD8+ CD30+ pseudolymphoma. *Br J Dermatol* 2001; 145: 650–652.
87. Miranda-Romero A, Perez-Oliva N, Aragonese H, Bastida J, Raya C, Gonzalez-Lopez A, et al. Carbamazepine hypersensitivity syndrome mimicking mycosis fungoides. *Cutis* 2001; 67: 47–51.
88. Sidwell RU, Doe PT, Sinett D, Francis N, Bunker CB. Lymphocytoma cutis and chronic infection. *Br J Dermatol* 2000; 143: 909–910.
89. Steinmann A, Gummer M, Agathos M, Breit R. Erythema migrans arciforme et palpabile und Lymphocytic Infiltration of the Skin – unterschiedliche Erscheinungsformen derselben Entität? *Hautarzt* 1999; 50: 270–274 (in German).
90. Shelley WB, Shelley ED. Pseudolymphoma at site of clonidine patch. *Lancet* 1997; 350: 1223–1224.
91. Houck HE, Wirth FA, Kauffman CL. Lymphomatoid contact dermatitis caused by nickel. *Am J Contact Derm* 1997; 8: 175–176.
92. Amann U, Luger TA, Metz D. Lichenoid- pseudolymphomatöse Tätowierungsreaktion. *Hautarzt* 1997; 48: 410–413.
93. Kalimo K, Rasanen L, Aho H, Maki J, Mustikkamki UP, Rantala I. Persistent cutaneous pseudolymphoma after intradermal gold injection. *J Cutan Pathol* 1996; 23: 328–334.
94. Braddock SW, Harrington D, Vose J. Generalized nodular cutaneous pseudolymphoma associated with phenytoin therapy. Use of T-cell receptor gene rearrangement in diagnosis and clinical review of cutaneous reactions to phenytoin. *J Am Acad Dermatol* 1992; 27: 337–340.
95. Blazejak T, Holzle E. Phenothiazin- induziertes Pseudolymphom. *Hautarzt* 1990; 41: 161–163.